



# SERI Surgical Scaffold as an Adjunct to Conventional Brachioplasty

AQ1

Andrew N. Kornstein,  
MD, FACS

**Summary:** Although the popularity of longitudinal brachioplasty has grown tremendously in recent years, dealing with the unpredictable scar remains a challenge for the surgeon and the patient. The scar often heals slowly and widens over time, perpetuated by the effects of gravity, body movements, and the thin nature of the superficial fascial system (SFS) of the arm. Scar widening may correlate with recurrence of the soft-tissue deformity as the repaired underlying SFS stretches. Therefore, techniques that support and stabilize the SFS are highly desirable for addressing the problematic scar. In the present case, the author used a silk-derived surgical scaffold (SERI) as an adjunct to conventional brachioplasty. SERI provided the requisite support for the patient's SFS, resulting in a faster maturation process and a better-quality scar. This stands in stark contrast to the majority of longitudinal brachioplasty results reported in the medical literature. (*Plast Reconstr Surg Glob Open* 2014;XXX:00-00; doi: 10.1097/GOX.000000000000155; Published online Day Month 2014.)

**B**rachioplasty is surging in popularity. More than 15,000 upper-arm lifts were performed in the United States in 2012.<sup>1</sup> The rate of brachioplasty procedures has risen by 4473% in the past 12 years.<sup>1</sup> However, a common concern remains—the scar associated with conventional (longitudinal) brachioplasty.

AQ3 In a multicenter review of 96 patients who have undergone brachioplasty, it was found that the most common complication was hypertrophic scarring, which occurred in 24% of patients and required revisional surgery in some cases.<sup>2</sup> The scar often heals poorly and widens postoperatively,<sup>2,3</sup> despite the sur-

geon's efforts to optimize its location and quality. Numerous attempts to improve surgical techniques have been introduced, including Lockwood's<sup>4</sup> suggested suspension to the clavicular fascia and Goddio's<sup>5</sup> use of deepithelialized overlapping flaps. However, scarring and revision rates remain high.<sup>2,5</sup>

Thus, alternatives that obviate or minimize the scar are highly desirable. Options include noninvasive skin-tightening procedures and minimal-incision brachioplasty (ie, axillary, horizontal). However, not all patients are candidates for these procedures, and therefore the desired aesthetic outcome may not be achievable.

An important advancement in longitudinal brachioplasty is to place the incision more caudally (from medial epicondyle to caudal axilla) rather

AQ2 *From the Museum Mile Surgery Center, New York, N.Y.*

*Received for publication May 8, 2014; accepted May 13, 2014.*

*Dr. Kornstein is in private practice in New York City, N.Y., and is also a member of Split Rock Surgical Associates in Wilton, Conn.*

*Copyright © 2014 The Authors. Published by Lippincott Williams & Wilkins on behalf of The American Society of Plastic Surgeons. PRS Global Open is a publication of the American Society of Plastic Surgeons. This is an open-access article distributed under the terms of the Creative Commons Attribution-NonCommercial-NoDerivatives 3.0 License, where it is permissible to download and share the work provided it is properly cited. The work cannot be changed in any way or used commercially.*

DOI: 10.1097/GOX.000000000000155

**Disclosure:** *The author has no financial interest to declare in relation to the content of this article. Writing and editorial assistance was provided to the author by Lynda Seminara of ClearView Medical Communications, Cherry Hill, N.J., and it was funded through a publication grant by Allergan, Inc., Irvine, Calif., at the request of the investigator. Allergan, Inc. was not involved in the development of the manuscript. Neither honoraria nor payments were made for authorship by Allergan. The Article Processing Charge was paid for by the author.*

AQ4

than in the bicipital groove. This preferential position is more effective for concealing the scar when the arms are elevated or are resting at the side of the body. However, even fine scars tend to widen over time due to gravitational forces and the thin skin and superficial fascial system (SFS) in this region. In the author's opinion, this fascial weakness is responsible for the protracted healing seen with scars in this location. Cutaneous scar hypertrophy compensates for subjacent fascial support deficiency. Hence, the decision to proceed with conventional brachioplasty must be made cautiously, weighing all potential benefits and risks, including the possibility of a conspicuous scar.

The SERI Surgical Scaffold (Allergan, Inc., Irvine, Calif.) may strengthen the SFS and thus protect against progressively widening scars. Cleared by the US Food and Drug Administration in 2009, SERI is indicated for use as a transitory scaffold for soft-tissue repair and support.<sup>6</sup> It is designed to reinforce deficiencies where weaknesses exist. SERI has been used successfully in aesthetic and reconstructive breast surgery, with high rates of physician and patient satisfaction.<sup>7</sup> This knitted multifilament material is derived from silk that has been purified by the BIOSILK process (Allergan, Inc.), which yields ultrapure fibroin. After implantation, SERI is replaced by the body's own collagen, in proportion to the stress placed on the wound. As bioresorption occurs, load-bearing responsibility is transferred to the new tissue ingrowth, allowing maintenance of mechanical integrity at the surgical site.<sup>6</sup>

The following case demonstrates that SERI can provide effective support for the SFS when applied to conventional brachioplasty, which may prevent the scar from widening postoperatively. To the author's knowledge, this is the first report of SERI's use for scar refinement in body contour surgery. Recently, the author performed a similar procedure in circumferential body lift surgery.

## CASE PRESENTATION

This 46-year-old female massage therapist had a lifelong struggle with pendulous upper arms. Noninvasive skin shrinkage [5 treatments of Exilis (BTL Industries, Framingham, Mass.)] had failed to produce significant clinical results. At initial presentation, she weighed 220 lb and had been deemed a candidate for minimal-incision (axillary) brachioplasty combined with subsequent Exilis treatments to remedy any residual laxity. However, after subsequent weight loss (45 lb) that produced additional excess skin, this treatment was no longer an option. Conventional brachioplasty was required. Her preoperative body weight was 175 lb.

In light of SERI's favorable clinical record<sup>7,8</sup> and theoretical advantages for conventional brachioplasty, the addition of this scaffold was recommended to the patient and she consented.

Surgical markings were made preoperatively. Those for lipoplasty were performed topographically. The procedure was aimed at sculpting the lateral and posterior arm and reducing volume elsewhere, with the resultant scar being at the junction of the medial and posterior arm. A tailor tack-finger pinch method was used to plan the resection, with perpendicular guide markings to ensure accurate closure. In November 2013, the patient underwent primary conventional brachioplasty with lipoplasty and high lateral tension abdominoplasty.

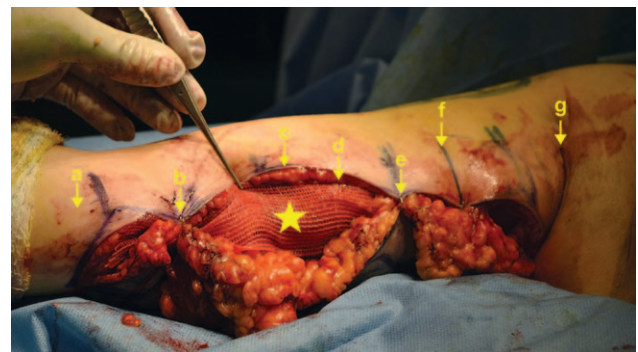## Implantation of SERI Surgical Scaffold

Before SFS closure, SERI was implanted according to the manufacturer's instructions.<sup>6</sup> In preparation for placement between the cut edges of the upper-arm SFS, 2 pieces of SERI were fashioned (one for each arm), each measuring approximately 2×25 cm. A triangulation suture of 3-0 Mersilene (Ethicon, Cornelia, Ga.) was used to close the SFS interposing the SERI Scaffold. Final closure was performed with 2-0 Quill Monoderm (Surgical Specialties Corp., Reading, Pa.) in the deep dermis, creating an everted closure ridge. Prineo tape (Ethicon) was the final dressing. The surgical technique is shown in Figures 1 and 2.

F1,F2

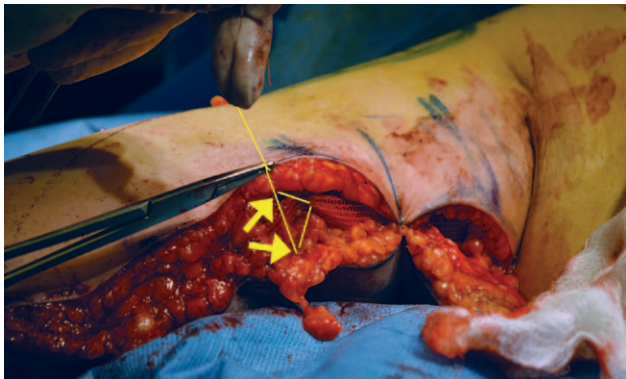
## Results and Follow-up

A lipoplasty support garment was placed immediately after surgery and was worn by the patient until she was comfortable without it (~5 weeks). She received monthly follow-up and returned to her work as a massage therapist just 1 month postoperatively.



**Fig. 1.** Intraoperative view demonstrates the position of the single layer of SERI that was placed in the excisional wound before closure of the SFS. Star indicates SERI Surgical Scaffold; a, antecubital fossa of the arm; b, temporary tacking staple; c, skin edge and subcutaneous tissue; d, layer of the SFS; e, temporary tacking staple; f, closure alignment markings; g, axilla.

## Kornstein • SERI in Conventional Brachioplasty



**Fig. 2.** Intraoperative view demonstrates closure of the SFS layer with SERI interposed between the SFS-free edges, using a triangulation suture (SFS-SERI-SFS). Arrows indicate triangulation suture from SFS to SERI to SFS on the opposing side.

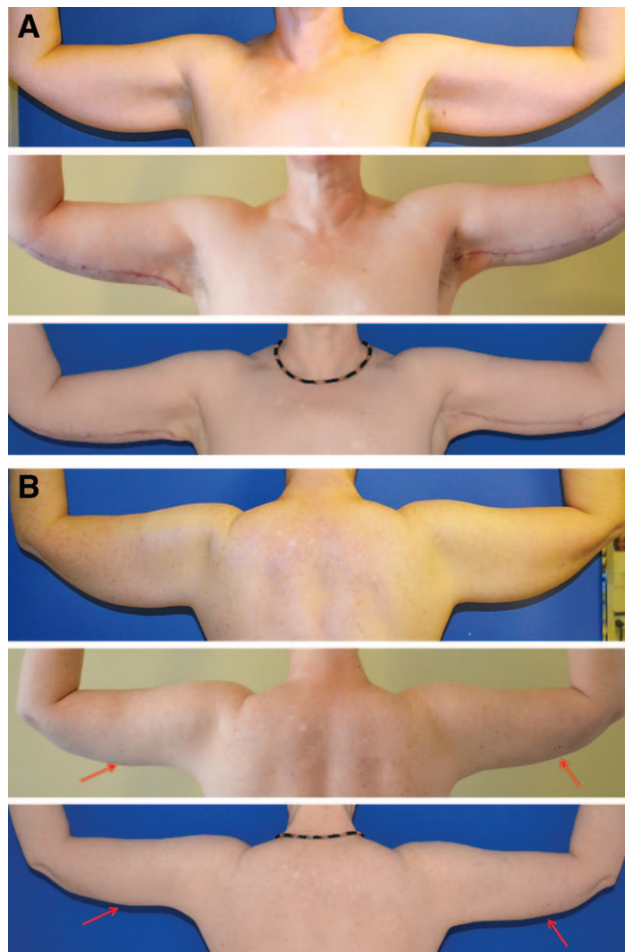
Scar care consisted of the use of a paper tape for the initial 6 weeks following surgery plus daily digital pressure (scar blanching) massage until the scar became flat and soft.

Six months postoperatively, there was no evidence of scar widening (Fig. 3, bottom panels). Scar fading was observed, and skin color had returned to normal at various locations along the scar line. Moreover, there was no apparent recurrence of the soft-tissue deformity. Use of the 6-month time point was extrapolated from the study by Hurwitz et al,<sup>9</sup> who observed that surgical correction of the saddlebag deformity was stable by 6 months postoperatively.

### DISCUSSION

The desire for thin well-toned arms has increased profoundly in recent years, likely fueled by sleeveless fashions and images of extremely fit celebrities.<sup>1,10</sup> Many procedures to enhance the appearance of the arms exist, ranging from skin tightening (with/without fat reduction) to nonsurgical fat removal to various surgical modalities. Many patients are not good candidates for noninvasive or minimal-incision techniques, and therefore they require conventional (longitudinal) brachioplasty for which scarring remains a problem and a major deterrent. The combination of gravity, thin skin, and a thin SFS can lead to widening of the scar.

Cosmetic surgical procedures must be tailored to optimize aesthetic outcomes, including location and quality of scarring. SERI may be beneficial in conventional brachioplasty because it is a strong biocompatible bioprotein that provides immediate physical and mechanical stabilization of soft tissue.<sup>6</sup> Frequent motion and gravitational forces may delay the healing of scars and cause them to widen as they hypertrophy in response to local stresses. Reinforc-



**Fig. 3.** Anterior (A) and posterior (B) clinical photographs obtained preoperatively (top panels), 1 month after conventional brachioplasty in which the SERI Surgical Scaffold was implanted (center panels), and 6 months after the surgery (bottom panels). The bottom anterior image demonstrates stable scar healing (width), with fading and skip areas already present along the scar line. The bottom posterior image shows stability of the soft-tissue correction, as evidenced by the stable nevi (red arrows).

ing the SFS during brachioplasty may minimize or inhibit scar expansion.

This case demonstrates that scar width and soft-tissue contour can remain stable if SERI is used in conventional brachioplasty. It stands to reason that candidates for body contour surgery would have damaged soft tissues, including the SFS components used for repair. SERI may function to qualitatively rehabilitate the “tissue clay” with which surgeons sculpt.

### CONCLUSIONS

SERI is a promising adjunct to conventional brachioplasty when implanted with precision by experienced surgeons in appropriate candidates. It seems to provide additional strength to the soft-tissue

“clay” that surgeons must sculpt, and thus it may inhibit widening of the scar, a common concern with brachioplasty. Experience in more patients is warranted to confirm the safety and efficacy of SERI in brachioplasty.

**Andrew N. Kornstein, MD, FACS**

1050 Fifth Avenue

New York

NY 10028

E-mail: andrewkornstein@gmail.com

### REFERENCES

1. American Society of Plastic Surgeons. *2012 Plastic Surgery Statistics Report*. 2013. Available at: <http://www.plasticsurgery.org/Documents/news-resources/statistics/2012-Plastic-Surgery-Statistics/full-plastic-surgery-statistics-report.pdf>. Accessed December 12, 2013.
2. Zomerlei TA, Neaman KC, Armstrong SD, et al. Brachioplasty outcomes: a review of a multipractice cohort. *Plast Reconstr Surg*. 2013;131:883–889.
3. Bossert RP, Dreifuss S, Coon D, et al. Liposuction of the arm concurrent with brachioplasty in the massive weight loss patient: is it safe? *Plast Reconstr Surg*. 2013;131:357–365.
4. Lockwood T. Brachioplasty with superficial fascial system suspension. *Plast Reconstr Surg*. 1995;96:912–920.
5. Goddio AS. A new technique for brachioplasty. *Plast Reconstr Surg*. 1987;84:85–91.
6. Allergan, Inc. *SERI® Surgical Scaffold Product Information. IFU-SCFLD-001 Rev K*. Irvine, CA: Allergan, Inc.; 2013.
7. Jewell M, Lehfeltd M, Downey S, et al. Clinical experience with the SERI™, a silk-derived bioresorbable scaffold, in two-stage implant-based breast reconstruction. Poster presented at: 17th World Congress of the International Confederation for Plastic, Reconstructive, and Aesthetic Surgery (IPRAS); February 24–March 1, 2013; Santiago, Chile.
8. Gross JE. Use of SERI Surgical Scaffold for soft-tissue support in a massive weight loss patient. *Plast Reconstr Surg Glob Open*. 2013;1:e86.
9. Hurwitz DJ, Rubin JP, Risin M, et al. Correcting the saddlebag deformity in the massive weight loss patient. *Plast Reconstr Surg*. 2004;114:1313–1325.
10. Goldsmith B. Surge in arm lift surgery prompts warnings over scarring. 2013. Available at: <http://www.reuters.com/article/2013/04/30/us-surgery-arms-idUSBRE-93T0U020130430>. Accessed December 12, 2013.

# AUTHOR QUERIES

## **AUTHOR PLEASE ANSWER FOR ALL QUERIES**

AQ1—Please note that "A Case Report" has been deleted from the article title.

AQ2—Please approve the affiliation details of the author. Also, provide departmental affiliation, if appropriate.

AQ3—Please confirm the edits to the sentence "In a multicenter review of 96 patients..."

AQ4—Please confirm the disclosure statement, especially the statement regarding the party responsible for paying for the Article Processing Charge.